

**How to manage bleeding
(clip vs electrocoagulation)
and perforation
(clip vs surgery):
video cases**

Dr. Brian Saunders

QUALITY IN ENDOSCOPY

**COLONOSCOPY &
COLONIC NEOPLASMS**

Berlin, Germany May 4 - 5, 2012

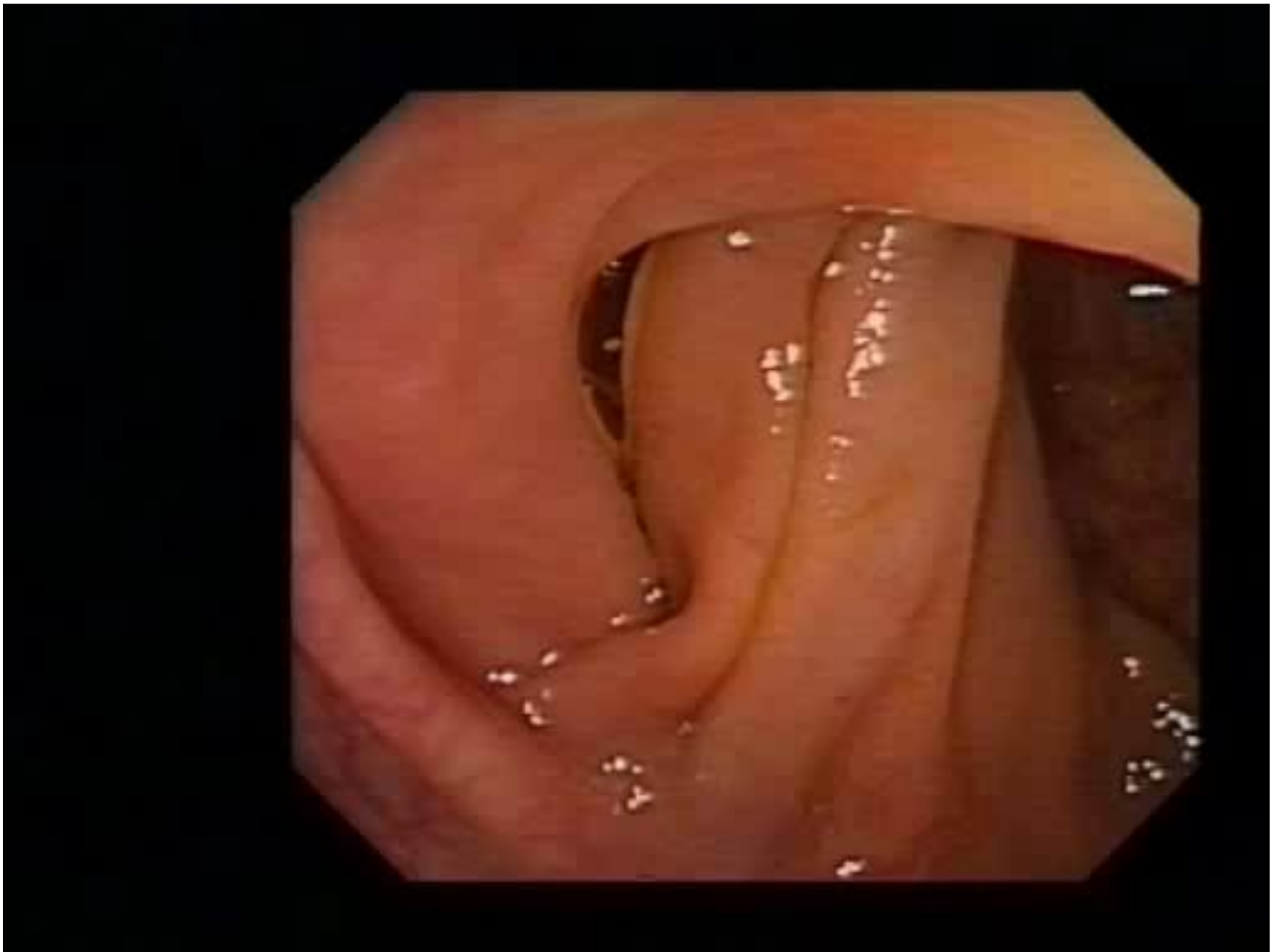


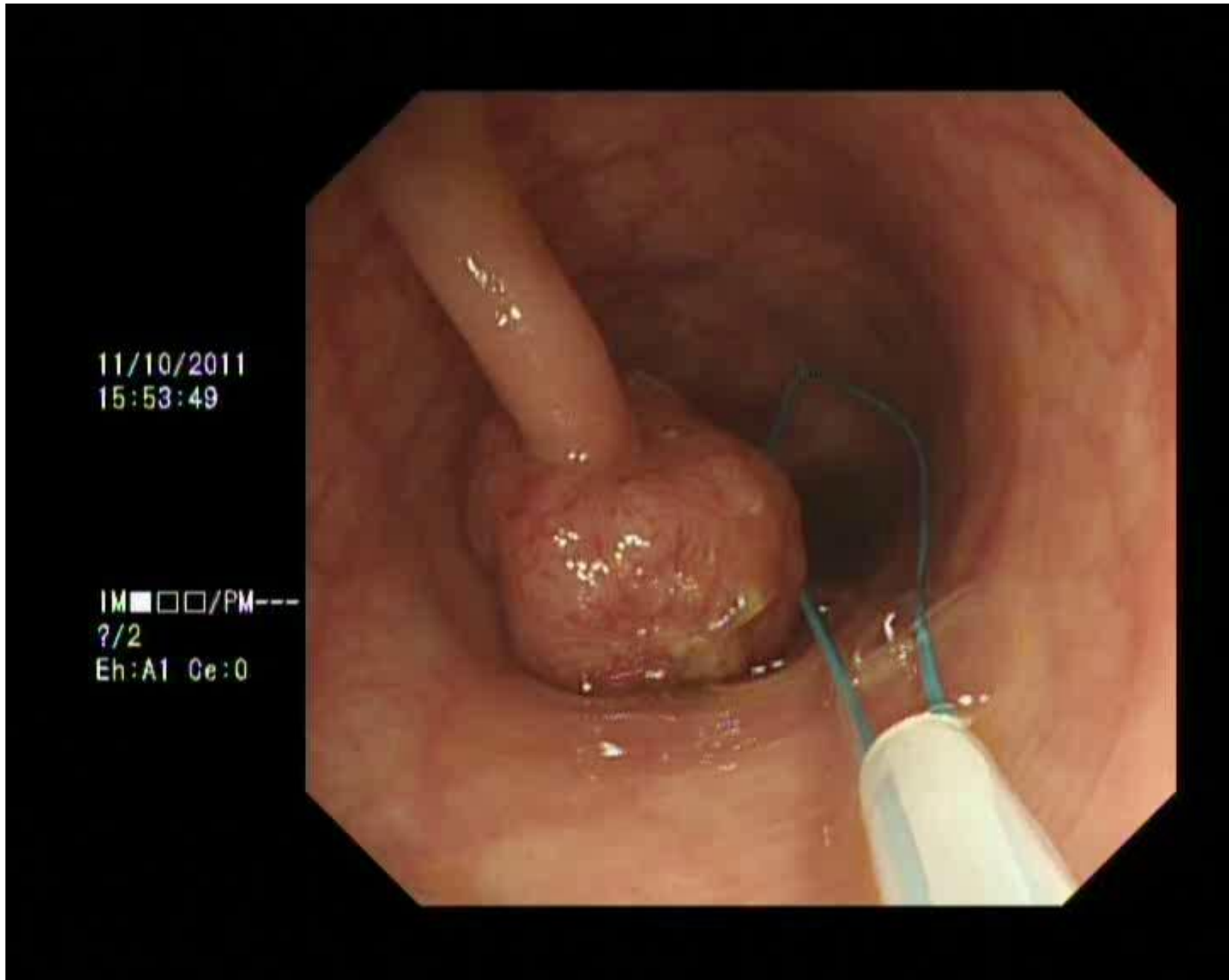
www.quality-in-endoscopy.org

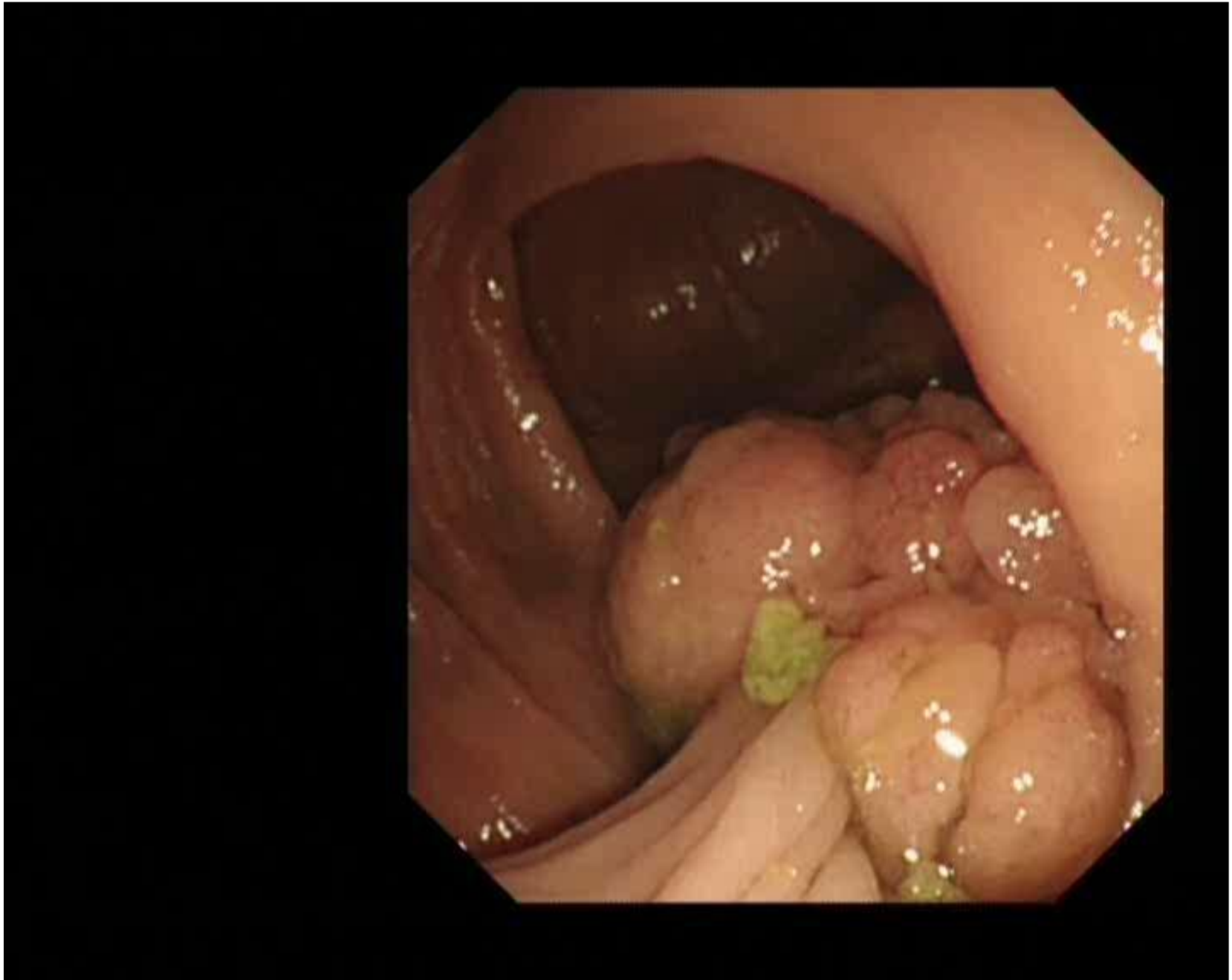Bleeding post-polypectomy

- ◆ **Post- polypectomy (0-4%)**
 - immediate or delayed for 3 weeks
 - increased risk
 - size of polyp
 - proximal location
 - anticoagulants (not low dose aspirin)
 - poor bowel preparation
 - patient age
 - chronic renal disease

- ◆ **cold forceps/snare - delayed bleeding very rare**







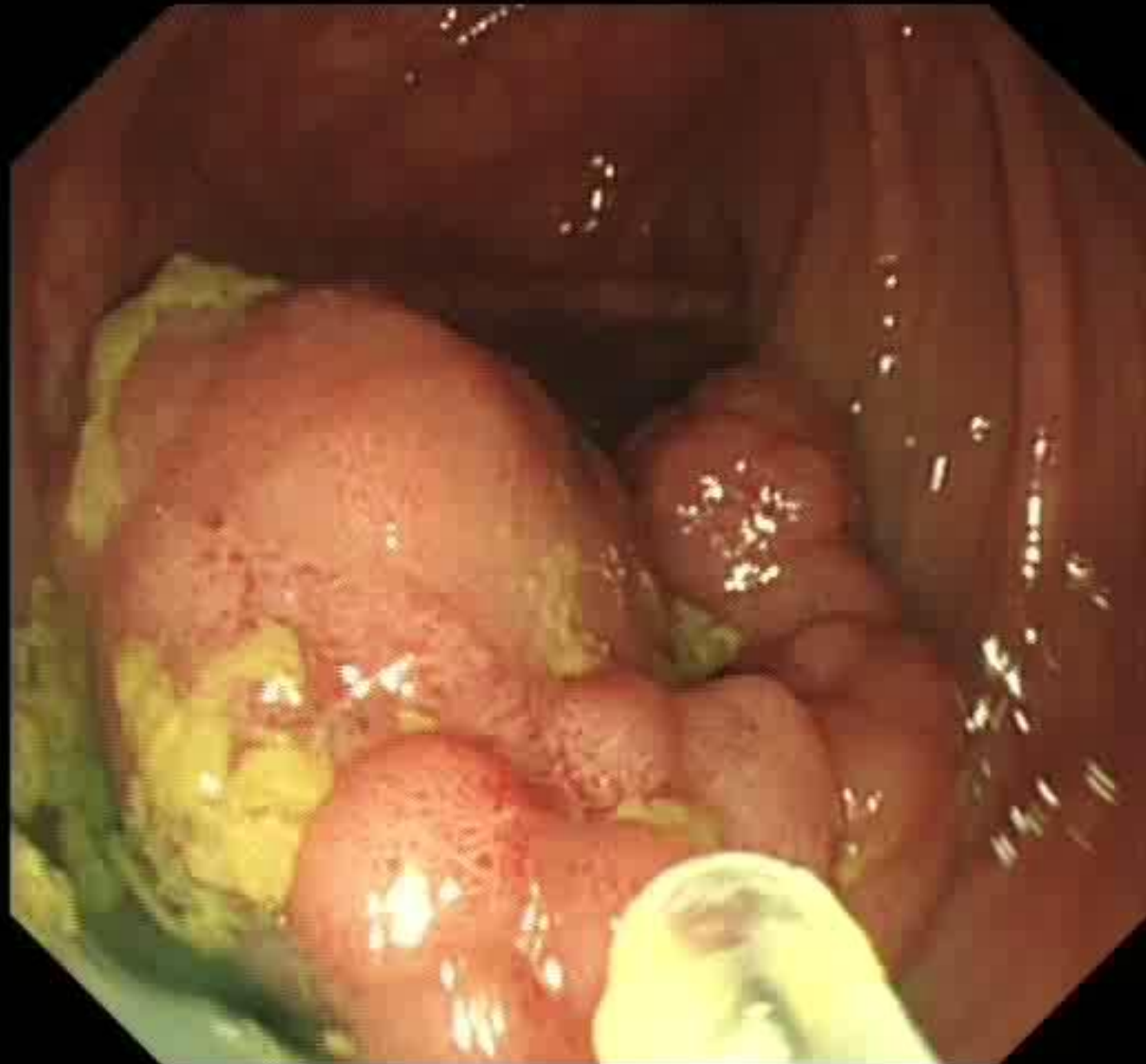
Age :
D.O.Birth :

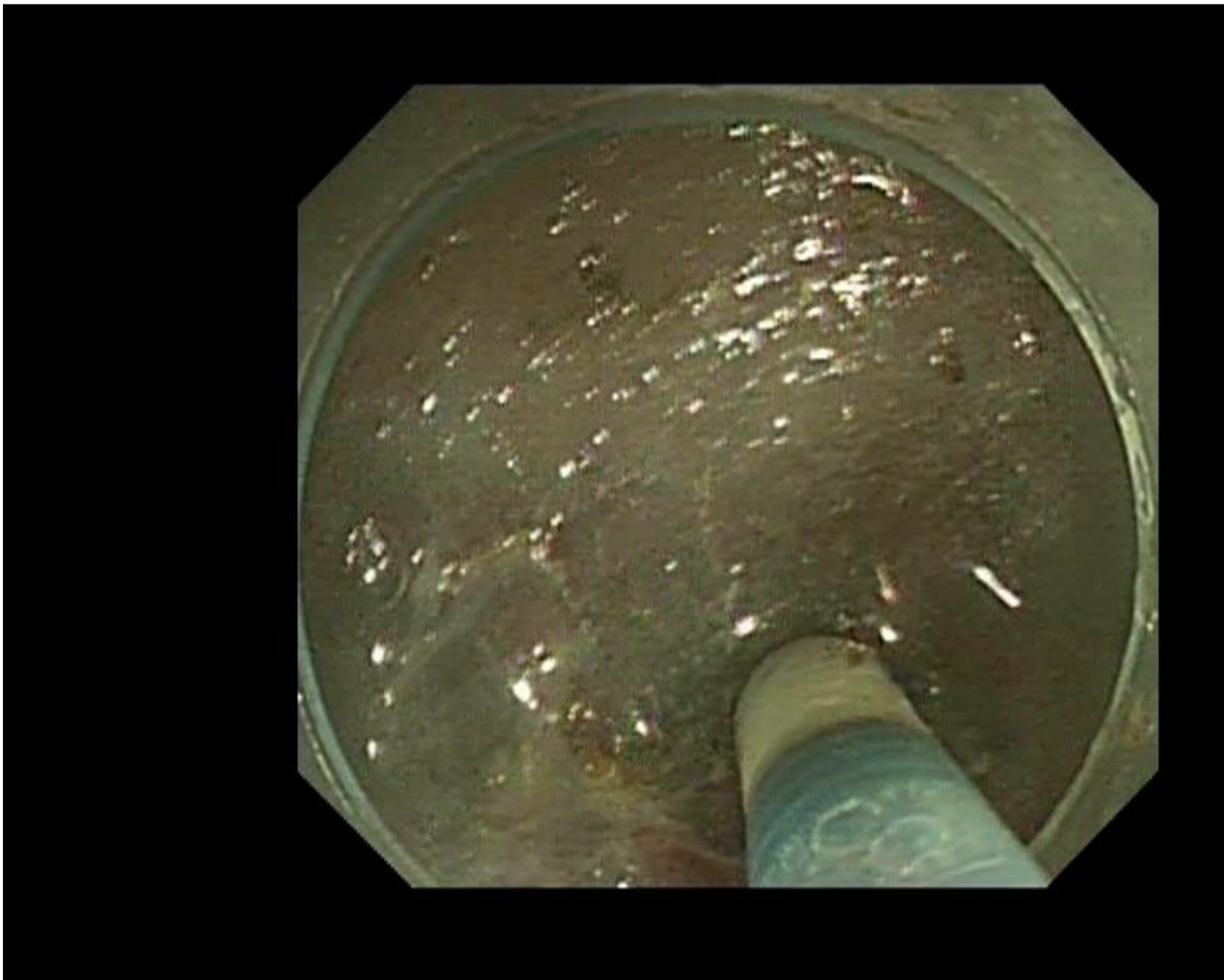
07/10/2010
08:47:22

SCV:27

CT: N EH: A1
CE: 0 Z: 1.0

Physician :
Comment :





Perforation –post polypectomy (1/100 -1/1500*)

- **Immediate**
 - **Clip defect?**
 - **Decompress pneumoperitoneum**
 - **Antibiotics + surgical review**
 - **What was prep like?**
- **Delayed (1-5 days)**
 - **Peritonitis – surgery necessary**

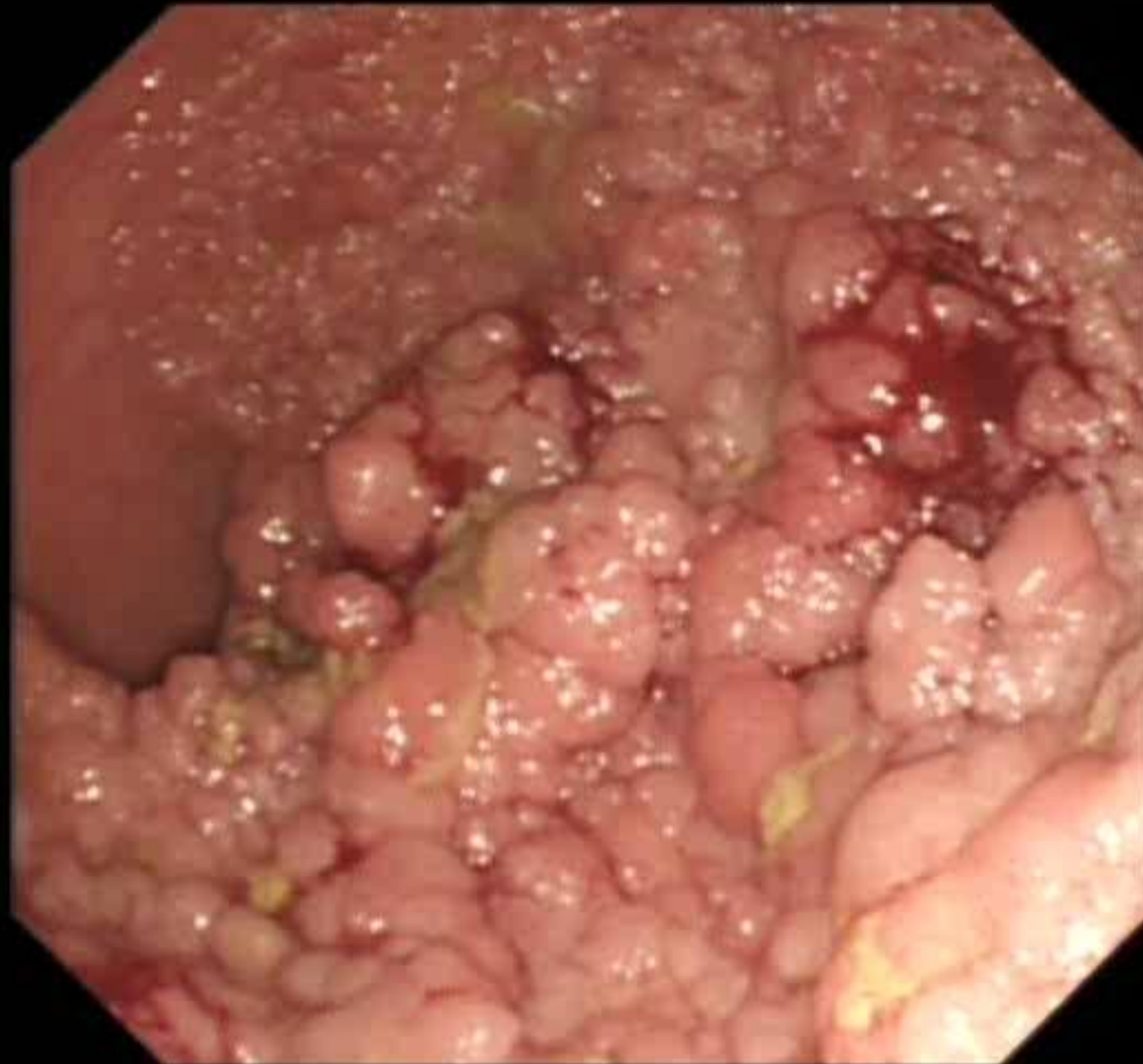
= Age :
D.O.Birth :

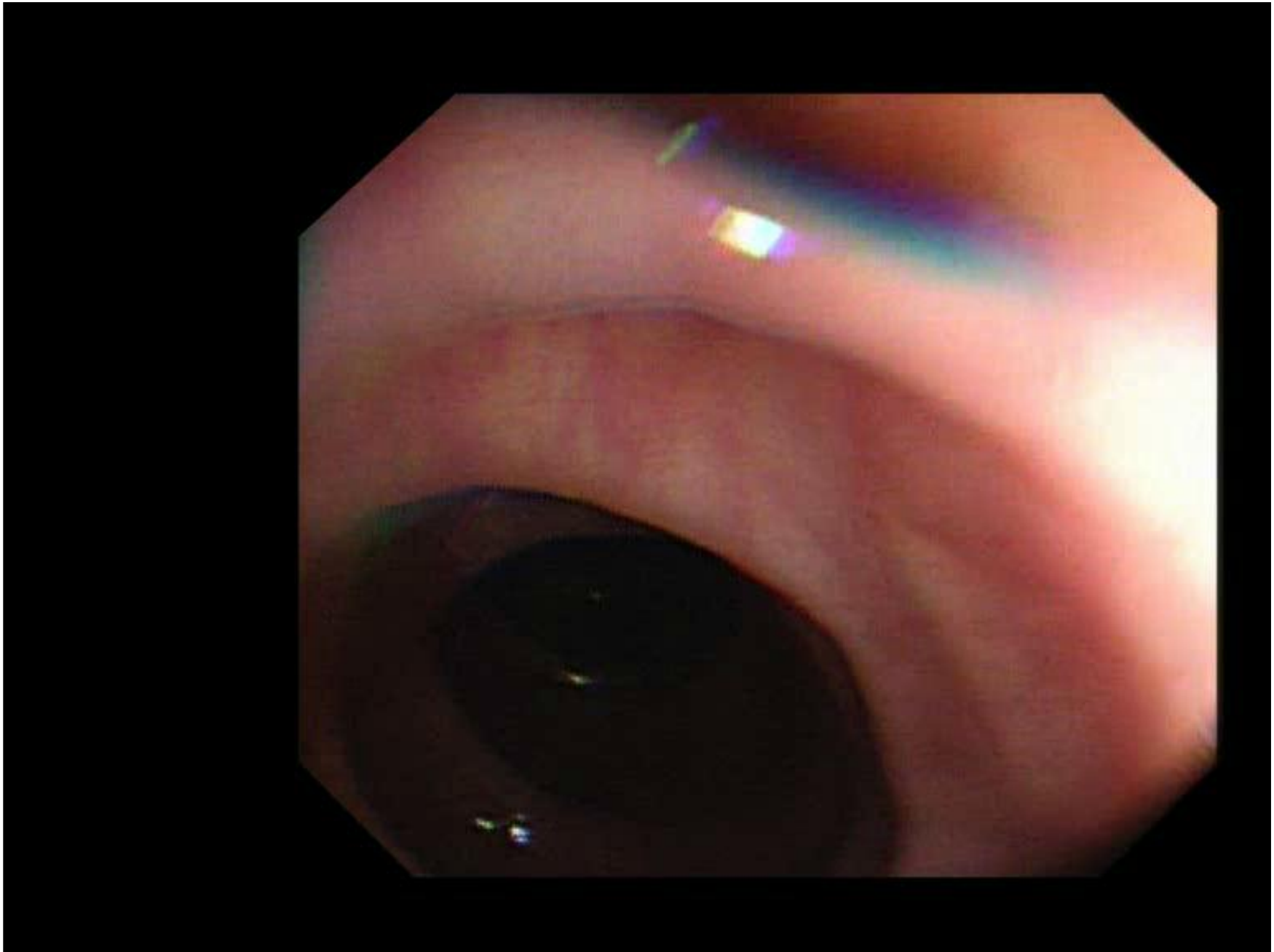
08/09/2011
15:45:22

SCV:84

Cr: N E_H: A1
C_E: 0 Z: 1.0

Physician :
Comment :





Take Home Message

- ◆ **Equipment check-list prior to therapy**
- ◆ **Endoscopy team MUST be familiar with rapid set-up and use of clips and haemostatic devices**
- ◆ **If perforation occurs -decompress pneumoperitoneum**
- ◆ **Close working with surgical colleagues**